



PATIENT

Lucy Clarke

SPECIES

Canine

BREED

Coton De Tulear

SEX

Female Spayed

AGE

13 years

PRESENTING CLINICAL SIGNS

History: Progressive heart murmur, now grade 4/6. Exercise intolerance. Wheezing at times.
-Abnormal PE/Chem/CBC/UA Results: CBC normal, RBC/WBC/platelet morphology normal.
Chemistry - SDMA 19(0-14)Urea BUN 12.8(3.2-11.0)T4 normal, U/A sp. grav - 1.033 and 4+ Ca Ox crystals.

RADIOGRAPHIC FINDINGS *NOTE: Images submitted for supplemental cardiac information only.
Severe cardiomegaly without obvious evidence of CHF.

ECHOCARDIOGRAM FINDINGS

2D, m-mode and Doppler imaging are available. Diffuse thickening of mitral valve leaflets (anterior > posterior) with prolapse into the left atrial lumen. Severe eccentric mitral regurgitation with severe left atrial dilation. Significant LV dilation with hyperdynamic myocardial function. The tricuspid valve appears mildly thickened, with mild tricuspid regurgitation. Normal velocity. Normal right heart. The pulmonic and aortic valves are normal in morphology and mobility. Normal pulmonic and aortic outflow velocities. No pulmonic or aortic insufficiency. No pericardial or pleural effusion noted. No cardiac tumors observed.

CARDIAC CHART

WEIGHT

11.2lbs

INTERPRETED BY

Maggie Machen Lamy,
DVM DACVIM
(Cardiology)

IMAGING PERFORMED BY

Crystal Hill, RVT

HOSPITAL NAME

Hawkins Animal
Hospital

REFERRING VET

Dr. Hawkins

CANINE CARDIAC PARAMETERS	MR VMAX (m/s)	TR VMAX (m/s)	LA/AO (Boon method)	LA/AO (Heart Base; Swe)	FS (%)	EF (%)	EPSS (cm)
NORMAL PARAMETER	4.5-5.5	<2.7	1.3	<1.6	28-40	40-100	<0.6
PATIENT	4.5	2.0	1.9	2.2	47	80	0.3
CANINE CARDIAC PARAMETERS	HR (BPM)	AV VMAX (m/s)	PV MAX (m/s)	BODY WEIGHT (kg)	LA 2D short axis Base view (cm)	LVIDd Avg; 2D and m-mode short axis (cm)	LVIDs Avg; 2D and m-mode short axis (cm)
NORMAL PARAMETER	50-100	0.7-1.7	0.7-1.6	BELOW	BELOW	BELOW	BELOW
PATIENT	190	1.3	0.8	5.1	3.1	3.8	2.0
*Normal chamber parameters expressed as a mean value (SD)				3	1.27 (5.3)	2.46 (2.46)	1.36 (5.5)
BODY WEIGHT DEPENDENT PARAMETERS				5	1.40 (4.5)	2.74 (5.2)	1.60 (4.7)
*Note: All measurements based upon multi-modal images and methods. An average value is reported.				10	1.50 (3.8)	3.27 (3.5)	2.06 (3.1)
				15	1.83 (2.0)	3.71 (2.4)	2.43 (2.1)
				20	2.02 (1.9)	4.14 (2.2)	2.80 (2.0)
				25	2.18 (2.4)	4.48 (2.9)	3.10 (2.5)
				30	2.33 (3.3)	4.83 (3.9)	3.39 (3.4)
				35	2.48 (4.3)	5.17 (5.0)	3.69 (4.5)
				40	2.62 (5.2)	5.48 (6.1)	3.96 (5.4)
				50	2.88 (7.1)	6.07 (8.3)	4.46 (7.4)

INTERPRETATION OF THE FINDINGS & FURTHER RECOMMENDATIONS

The cause of the murmur is chronic degenerative valve disease causing severe mitral and mild tricuspid regurgitation. Severe left atrial enlargement indicates the risk for spontaneous congestive heart failure is elevated. No additional issues such as systolic dysfunction are identified.

INVOICE

32259

DATE

8/9/23



PATIENT

Lucy Clarke

The patient is experiencing symptoms that are likely related to underlying structural disease. Even without congestion on the included chest radiographs, given the symptoms and echo findings, full lifelong cardiac support is recommended as below including Lasix therapy. Depending on clinical response to the medications, cough suppression may also be useful. Monitoring of sleeping breathing rates in the future will be paramount to determine the origin of any future cough. The average survival of canine patients with active pulmonary edema is 8-9 months on medications, however they generally are able to maintain a good quality of life for that period. Patient will always be at risk for recurrent CHF, development of arrhythmias/LA tear, syncope and/or sudden death in the future. Monitoring of renal values is recommended lifelong.

SPECIES

Canine

BREED

Conton De Tulear

SEX

Female Spayed

Omega fatty acid supplementation and mild salt restriction may also be of some long-term benefit. Monitor for development of a worsening cough, labored breathing, exercise intolerance or collapse episodes.

AGE

13 years

Elective anesthesia is not advised, as there is high risk for complication. Risk: benefit ratio should be considered. Consider consultation with and/or referral to a facility with an anesthesiologist. Should you elect to proceed, cardiac protective drug choices (opioid/benzodiazepine premedication, propofol or alfaxalone induction, iso or sevoflurane gas) are recommended. Pre-oxygenate for 5-10 minutes prior to induction and recover in O2 cage. Monitor for arrhythmias, hypotension, and hypoxia both intra and post-operatively and intervene as necessary. Moderate IV fluid restriction is recommended to avoid fluid overload, while considering comorbidities, hydration status, BP, etc. Avoid heart rate stimulating drugs such as atropine unless clinically indicated.

WEIGHT

11.2lbs

INTERPRETED BY

Maggie Machen Lamy,
DVM DACVIM
(Cardiology)

PLAN

Screening BP is recommended. Administer Pimobendan 0.3mg/kg PO q12h. Administer low dose furosemide/Lasix 1 mg/kg PO q12h. Administer spironolactone 1-2mg/kg PO q12h. Consider hydrocodone with homatropine (0.2-0.4mg/kg PO up to q4-6 hours PRN) if cough persists despite normal SRRs.

IMAGING PERFORMED BY

Crystal Hill, RVT

A renal panel and BP are recommended in 10-14 days, then every 3-4 months on diuretics to ensure tolerance of medications. If doing well at that time and BP >130mmHg, institute ACEI 0.5mg/kg PO q12h.

HOSPITAL NAME

Hawkins Animal
Hospital

A recheck echocardiogram is recommended in 6 months to screen for progression, sooner if clinical signs arise/persist.

REFERRING VET

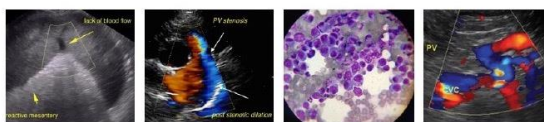
Dr. Hawkins

INVOICE

32259

DATE

8/9/23



PATIENT

Lucy Clarke

SPECIES

Canine

BREED

Conton De Tular

SEX

Female Spayed

AGE

13 years

WEIGHT

11.2lbs

INTERPRETED BY

Maggie Machen Lamy,
DVM DACVIM
(Cardiology)

IMAGING

PERFORMED BY

Crystal Hill, RVT

HOSPITAL NAME

Hawkins Animal
Hospital

REFERRING VET

Dr. Hawkins

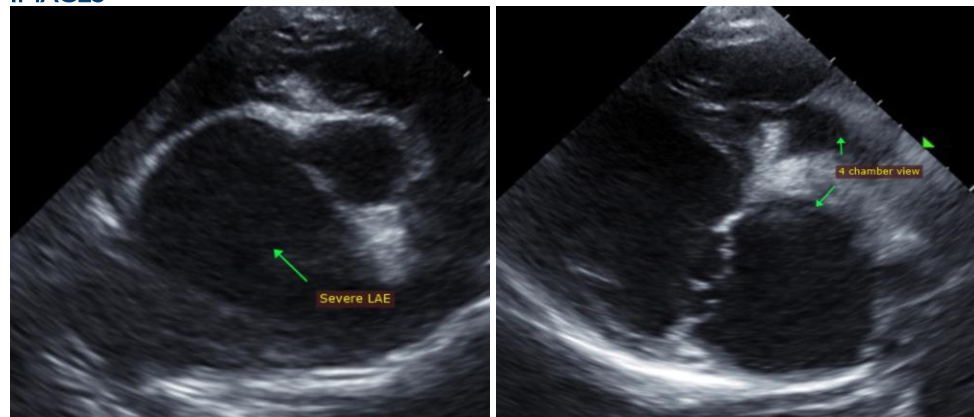
INVOICE

32259

DATE

8/9/23

IMAGES



The information and recommendations provided are based on the images presented by the referring veterinarian. No evaluation can be communicated regarding pathology that was not visible in the image/video clips provided.

Thank you for this referral. This report was generated using transcription software, and minor dictation errors may be present. If the clinical or image interpretation does not parallel your findings or if I can be of any further assistance, please contact me.

Maggie Machen Lamy, DVM
Diplomate of the American College of Veterinary Internal Medicine (Cardiology)
info@sonopath.com